1916
B32

Baumgartner

Development Of The Palate And The Definitive Choanae In The Pig.

DEVELOPMENT OF THE PALATE AND THE DEFINITIVE CHOANAE IN THE PIG

BY

RACHEL ANN BAUMGARTNER

A. B. University of Kansas, 1912

THESIS

Submitted in Partial Fulfillment of the Requirements for the

Degree of

MASTER OF ARTS

IN ZOOLOGY

IN

THE GRADUATE SCHOOL

OF THE

UNIVERSITY OF ILLINOIS

1916

1916
B32
20c16

UNIVERSITY OF ILLINOIS

THE GRADUATE SCHOOL

.....191

I HEREBY RECOMMEND THAT THE THESIS PREPARED UNDER MY SUPERVISION BY Rachel Ann Baumgartner

ENTITLED Development of the Palate and the Definitive Choanae in the Pig.

BE ACCEPTED AS FULFILLING THIS PART OF THE REQUIREMENTS FOR THE DEGREE OF Master of Arts.

C. Kingsley
In Charge of Thesis

Henry B. Ward
Head of Department

Recommendation concurred in:*

Committee on Final Examination*

*Required for doctor's degree but not for master's.

343169

Table of Contents.

Page.

Introduction.....1

Observations.(Description of Serial Stages).....2

Summary.....8

Literature Consulted.....10

Explanation of Plates.....14

Digitized by the Internet Archive
in 2014

http://archive.org/details/developmentofpal00baum

Development of the Palate and the Definitive Choanae in the Pig.

Introduction.

The development of the choanae and the palate have been studied quite extensively in many mammals, including the human embryo.

I have attempted in this paper to describe the development of the definitive choanae and its relation to the development of the palate in the pig.

Our knowledge of the points considered in this article, up to 1891, was summarized by Minot (1892,pp.,575-581),though without any discussion of the literature,his account being chiefly based on His.

Later than this are the papers of Hochstetter ('91) on the rabbit and sheep and ('92) man. Previous to Hochstetter the formation of the bucco-nasal membrane and its perforation was unknown.

Peters in 1902 reviewed the literature on the points of the development of the primitive palatal processes. Pölzl in 1904 reviewed the very earliest work on the human palate, beginning with Dursy, who in 1864 published the first description of this development. She compared this work with that of His, Kiebel and others before adding the results of her investigation.

Stadelmann in 1916 has given a detailed account of the development of the roof of the mouth in the sheep.

Material and Method.

This investigation was carried on by the study of surface view, dissection, and series of transverse sections of the pig embryo from 6.5 to 39 mm. long.

Wax reconstructions were made of the 17,20,30,and 39 mm. stages so that the direct serial relation of the parts could be more easily followed.

I desire to thank Professor J.S.Kingsley for his valuable suggestions and interested criticism during the progress of the investigation.

Observations.

In the six millimeter embryo there is a thickening of the ectoderm on either side of the head,in front of,lateral, and a little medial to the eye. These thickenings are the anlagen of the olfactory organs. Each thickening is elongate in the sagittal plane of the animal, is slightly excavate near the center, while the thickened marginal walls are due in part to a greater thickness of the ectodermal cells on the medial, lateral and dorsal walls, in part to the actual depression of the central portion of the layer. On the ventral side there is not the same thickening of the ectoderm , so that there is here a slight groove which extends from the central pit into the mouth just inside the occludent margin of the upper lip. The depression is the olfactory pit, its ventral prolongation is the oro-nasal groove. The groove is slight but it is to be noted that the epidermis at its bottom is thickened like that in the margins and center of the olfactory organ , and it is this thickened portion which forms,as will be seen later,the bucco-nasal membrane.

In an embryo eight millimeters long, the depression in each olfactory region is deeper than before, the median and lateral nasal processes which form the pit,are more pronounced,and there are similar,but slight changes in the region of the oro-nasal groove.

When the embryo is 10 mm. long, the pits are much deeper, so that each may be described as a blind sac, the inner end being 0.1 mm. within the head. The anterior part of the floor of this sac is formed by the thickened epidermis of the oro-nasal groove, but the epithelium of the hinder part of the sac is free from the more posterior oral epithelium.

At the same time the ventral ends of the median and lateral nasal processes are approaching each other and fusing from behind forward, so that all that persists of the groove is a v shaped notch upon the anterior surface of the upper lip. (At the dorsal end the fusion is not so great i.e.,the wall between the pit and the mouth cavity is thinner). The opening to the pit is the external nares, the thickened epithelium of the groove forms the material in which the respiratory duct and the choana are to be found later, but at this stage there is no definite connexion of the nasal pit or sac with the oral cavity.

The development of the nasal processes produces a broad shallow groove between the two external nares. Ventro-lateral to the naris is the depression of the lachrimal groove,extending from the eye to the medial part of the oro-nasal groove and separating the more lateral maxillary process from the frontal process.

In the twelve millimeter embryo each pit is deeper so that the inner end of the blind sac is 0.2 mm. within the head. The external nares is relatively smaller than before, and the distance between the nares of the two sides is relatively less than in the 10 mm. embryo. The nasal and oral cavities are completely separated. But the fused area at the hinder end is much thinner than elsewhere,

this part forming Hochstetter's bucconasal membrane. In front of this membrane, the ectodermal layer has disappeared in the middle of the fused area and mesenchyme has invaded this portion. The maxillary processes of the first visceral arch are fusing laterally with the lateral nasal processes,the line of the lacrimal groove being less distinct. At the same time the mandibular processes are fusing medially to form the definitive lower jaw.

At the seventeen millimeter stage the relative distance between the nares has diminished and, owing to the partial fusion of the median nasal processes, the groove between the nares is more obliterated, there being but a broad and very shallow indentation. This partial fusion of the nasal processes is the beginning of the formation of the nasal septum. At the same time with this fusion the head has elongated and the nasal tip is assuming a snout-like appearance. This forward growth of the tip of the snout is separated from the forehead by a wide and shallow depression. The lateral edge of the lateral nasal processes have fused with the maxillary processes on the lateral side of the head,and the lower outer margin of the upper jaw has a thickened lip. The mandibular processes are now fused in the middle line so that the lower jaw is formed,though still much receded. Because of this fusion the oral opening becomes a definite slit.

The bucco-nasal membranes, which in the previous stage separated the nasal and mouth cavities, have now broken through and thus given rise to the oral nasal ducts and secondary connexions between the nose and the mouth are established,this condition paralleling that found in the amphibia. The openings, the primitive choanae, in the roof of the mouth, formed by the breaking through of the bucco-nasal membrane are slit-like and elongate in the

sagittal plane and lie just within the margin of the jaws. On either side and behind them, but at a lower level, are the palatal processes, while from the anterior margin of the mouth cavity a slight elevation, the papilla palatina, projects between the choana The palatal processes, at present scarcely more than a ridge, extend downward and slightly inward from the inner occludent margin of the jaw. These processes are lateral to the fleshy tongue which is still attached to the floor of the mouth to the very tip.

When the embryo is twenty millimeters long the snout is becoming more suine, and the distinction between the snout and the forehead is more emphasized. At the same time the external nares are attaining their definitive position in the center of the end of the snout.

The palatal processes have become more distinct and their margins are directed more toward the median line, and hence are relatively nearer to the fleshy tongue. The extreme tip of the tongue is now no longer attached to the floor of the mouth. Between the median margin and the occludent margin of the jaw each palatal process is excavate longitudinally on its ventral surface so that each presents a shallow groove. Laterally each process now shows at its lateral margin a slight elevation, most marked posteriorly, the alveolar ridge. Each palatal process is crossed anterior to the mid-line by three transverse ridges, the first appearance of the palatal rugae.

Between the palatal processes, at the extreme anterior end, the choanae are still visible in the primitive roof of the mouth. They show slight change in form , except that they are more elongate than before.

The changes in the twenty-five millimeter embryo are slight.

The palatal processes have extended slightly farther inwards, and their median margins are becoming more undulating in outline as viewed from below, while in front they are beginning to fuse with the papilla palatina. With this change the primitive choanae are no longer visible in direct view, but can still be seen by looking in at an oblique angle. There is also an increase in the number of palatal ridges as well as in their length and prominence, except at either side of the series.

In the twenty-seven millimeter embryo the palatal processes have increased in extent, those of the two sides growing towards each other, so that they nearly meet at about the middle of the roof of the mouth, while in front and behind this region they gape more widely, the gap being somewhat hexagonal in form.

Sections show that the tongue rises into this opening, its dorsal surface nearly meeting the septum nasi formed by the tissue around the median plate of the ethmoid cartilage. The extension of the palatal folds is still largely in the vertical plane, and on either side there is, as yet, but a broad shallow groove where ducts are later to develop. These downward extensions of the processes, are much longer in the middle than at either end of the palatal region. The rugae palatinae are slightly longer than before, but they stop some distance from the median margin of the palatal processes.

In the thirty millimeter embryo the nasal and mouth cavities are separated except at the anterior and posterior ends, this separation being brought about by a change in the direction of the growth of the palatal processes. In the twenty-seven mm. form these were directed downward on either side of the tongue, but now

they have assumed a horizontal position and have fused above the tongue in the middle line for about half their length, the line of fusion being marked by a median raphe. In front of the fusion there is an oral opening in which the palatal papilla is still visible, taking up about half the length of the gap. Behind the fusion the palatal cleft continues back for some distance as a very narrow v-shaped slit.

Sections show that the union of the edges of the processes begins dorsally and progresses ventrally. At the anterior end of their fusion they are in contact with the nasal septum. At the hinder end where they have not yet united, the lower margins of the processes are again the first to separate. Along this line of fusion the epithelium of the two processes persists as a well-marked line in the sagittal plane and at a few points near the anterior end along this line of concrescence there are slight indications of invasions of mesenchyme. By this concrescence the primitive mouth cavity has been divided into two chambers, an upper, which eventually develops into the respiratory ducts, and a lower, the definitive oral cavity.

In front, the olfactory region is still in communication with the respiratory part of the upper chamber by means of the primitive choanae, but farther back olfactory and respiratory parts are completely separated by the union of the septum nasi with the walls of the head just lateral to border of the respiratory tract. This latter cavity is higher on either side than in the middle where the ventral protrusion of the vertical plate of the ethmoid (which now contain the first traces of the vomer) nearly meet, there being a slight raphe on the dorsal side of the line of fusion

of the palatal processes, corresponding to the one described above.

In the thirty-nine millimeter embryo the anterior opening between the mouth cavity and the primitive choanal region of the thirty mm. embryo has decreased in actual size, while the palatal papilla has united with the posterior margin of the opening so that there are now two canals, the foramina incisiva, which persist throughout life. The tip of the papilla is prominent on the oral surface, a condition which also persists.

The median fusion has progressed still further backward and there is now a v-shaped opening from the respiratory duct into the pharyngeal cavity. In section (fig 17) it is seen that the single respiratory duct of the previous stage has been divided into two for a considerable part of its length by the downward growth of the septum nasi and the fusion of its ventral edges with the side walls of the duct. With this there has been a relative deepening and narrowing of the duct. The figure illustrating this point is from a section cut a little obliquely so that on one side it shows the respiratory duct cut off, while on the other it is still in communication with the respiratory cavity.

In the roof of the mouth of the seventy mm. embryo the palatal rugae ~~shows~~ extend farther inward toward the mid-line; a few in the middle almost meet.

Summary.

1. The anlagen of the olfactory organs are two thickened excavate patches of ectoderm, formed on either side of the head a considerable distance apart, in front of, and medial to the eyes.

2. At a later stage each of the nasal pits is deeper and is

united with the angle of the oral cavity by means of an oro-nasal groove. The lateral, upper, and medial margins of these pits project thus forming the lateral and medial processes.

3. By a fusion of the lower inner margin of these processes the connexion bwtween the nasal and oral cavities is cut off by a membrane.

4. Later as the pits deepen, the membrane between them breaks through, and thus the primitive choanae, passages between the nasal and primitive mouth, are formed.

5. Palatal processes grow into the oral cavity from either margin of the upper jaw, at a lower level than the primitive choanae. As these grow inward toward the mid-line, palatal rugae are developed on the ventral surface. At first there are but two or three of these, then more appear with increasing age.

6. The palatal processes fuse in the middle line except at the anterior and posterior ends. This fusion divides the mouth cavity into two, an upper respiratory and a lower secondary mouth cavity. The palatal papilla projects downward into the anterior opening. Posteriorly there is an elongate v-shaped slit.

7. The anterior opening has decreased, the palatine papilla has united with the anterior margin of the fused processes, so that there are now two canals, the foramina incisiva, which persist throughout life.

8. Later, the partitions formed by the palatal processes fuse dorsally in the mid-line with the nasal septum and thus the upper respiratory cavity is divided and each duct communicates with the mouth cavity at the posterior end.

Literature Consulted.

Balfour, F. M.

1881. Comparative Embryology.

Boas, von J. E. V.

1914. Die Schläfenüberdachung und das Palatoquadratum in ihrem Verhältnis zum übrigen Schädel bei den Dipnoern und den terrestren Wirbeltieren. Morph. Jahr. Vol. 49.

Corning, H. K.

1907. Lehrbuch der Topographischen Anatomie für Studierene und Ärzte.

Ellenberger, W., and Baum, H.

1906. Vergleichende Anatomie der Haustiere.

Fischer, E.

1901. Chondocranium von Talpa europaea. Anatomische Hefte, Bd. 17.

Frits, G. P.

1914. Beiträge zur vergleichenden Anatomie und Embryologie der Nase der Primaten. Morph. Jahr., Vol. 48.

Hochstetter, F.

1891. Über die Bildung der inneren Nasengänge oder primitiven Choanen. Verh. Anat. Ges., V Versammlung.

1892. Über die Bildung der primitiven Choanen beim Menschen. Verh. Anat. Ges., VI Versammlung.

Hertwig, O.

1910. Entwicklungsgeschichte des Menschens und der Wirbeltiere. 9 Auflage.

Inouye, M.

1912. Die Entwicklung des sekundaren Gaumens einiger

Säugetiere mit besonders Berücksichligung der Bildungsvorgänge am Gesichte und des Umlagerungsprozesses der Gaumenplatten. Anat. Hefte., Bd. 46.

Kellicott, W. E.

1913, Chordate Development.

Kiebel, F.

Studien zur Entwicklungsgeschichte des Schweines.

1893. Zur Entwicklungsgeschichte und vergleichenden Anatomie der Nase und des oberen Mundrandes bei Vertebraten. Anat. Anz. , Vol. 8.

Kingsley, J. S.

1912. Comparative Anatomy of Vertebrates.

Mihalkovics, V.

1898. Nasenhohle und Jacobson'sches Organ. Anat. Hefte.,Bd. 11.

Merkel, F.

1892. Jacobson'sches Organ und Papilla palatina beim Menschen. Anat. Hefte., Bd. I.

Meade, C. S..

1909. The Chondocranium of an Embryo Pig. Amer.Jour. of Anat. Vol. 9.

Minot, C. S.

1893. Human Embryology.

1903. A Laboratory Text-book of Embryology.

Olmstead,M. P.

1901. Das Primordialcranium eines Hunde Embryo. Anat. Hefte Vol. 43.

Pölzl, Anna.

1904. Zur Entwicklumgsgeschichte des menschlichen Gaumen. Anat. Hefte., Vol. 27.

Peter, Karl.

1902. Zur Bildung des primitiven Gaumens bei Mensch und Säugetieren. Anat. Anz., Vol. 20.

Parker, W. K.

1874. On the Structure and Development of the Skull of the Pig. Phil. Trans., Vol. 164.

Pohlman, E.

1910. Die embryonale Metamorphose der Physiognomie und der Mundhöhle des Katzenkopfes. Morph. Jahrb., Bd. 41.

Stadelmann, F.

1916. Die sog. Gaumenfortsätze und die Umlagerung des Gaumens. Kritische Studien an Embryonen des Schafes und des Schwein. Morph. Jahrb., Vol. 50.

Schorr, G.

1908. Zur Entwicklungsgeschichte des sekundären Gaumens bei einigen Säugetieren und bei Menschen. Anat. Hefte.,Vol.36.

Sicher, H.

1915. Die Entwicklung des sekundären Gaumens beim Menschen. Anat. Anz., Vol. 47.

Sisson, S.

1914. The Anatomy of Domestic animals.

Seydel, Otto.

1891. Uber die Nasenhöhle der hoheren Säugetiere und des Menschen. Morph. Jahrb., Vol. 17.

Terry, R. J.

1909. An observation on the development of the Mammalian vomer. Anat. Record. Vol.3.

Weber, N.

1904. Die Säugetiere.

Wiedersheim, , R.

1909. Vergleichende Anatomie der Wirbeltiere. VII Auflage.

1908. Der Bau des Menschen als Zeugnis für seine Vergangenheit.

Explanation of Plates.

Abbreviations.

Al. R., Alveolar ridge.

B. n., Bucco-nasal membrane.

D., Dental ridge.

E., Epithelium in the fusion area of the nasal processes.

Fo. In., Opening of the Foramina Incisiva into the mouth.

L. P., Lateral nasal process.

M. b., Bucco-nasal membrane.

M. P., Median nasal process.

N. P., Nasal pit.

N. S., Nasal septum.

O. c., Oral cavity.

P. b., Blind sac.

P. Ch., Primitive choana.

P. O., Primitive oral cavity.

P. P.,Palatal processes.

Pr., Palatal rugae.

Rd., Respiratory duct.

T., Tongue.

V., Vomer.

Plate I.

Fig. 1. Frontal view of the head of the 12 mm. pig embryo.

Fig. 2. Ventral view of the roof of the primitive mouth of the 17 mm. embryo.

Fig.,3. Ventral view of the roof of the primitive mouth of the 20 mm. embryo.

Fig.,4. Ventral view of the roof of the primitive mouth of

the 25 mm. embryo.

Fig. 5. Ventral view of the roof of the primitive mouth of the 27 mm. embryo.

Fig. 6. Ventral view of the roof of the secondary mouth of the 30 mm. embryo.

Fig. 7. Ventral view of the roof of the secondary mouth of the 39 mm. embryo.

Fig. 8. Ventral view of the roof of the secondary mouth of the 70 mm. embryo.

Plate II.

Fig. 9. Cross-section of the head of the 12 mm embryo, slightly oblique, thus showing on one side, the fused processes where mesenchyme has invaded the area, on the other, the bucco-nasal membrane.

Fig. 10. Cross-section of the head of the 12 mm. embryo posterior fig. 9, showing the union of the processes on one side and the blind sac on the other.

Fig. 11. Cross-section through the head of a 17 mm. embryo showing primitive choanae.

Fig. 12 Cross-section through the anterior region of the head of a 27 mm embryo showing the shorter palatal processes.

Fig. 13. Cross-section through the head of a 27 mm. embryo posterior to fig. 12, to show the processes longer in this middle region.

Fig. 14. Cross-section of the head of the 30 mm. embryo, showing the anterior communication of the nasal and mouth cavities.

Fig. 15. Cross-section through the head of the 30 mm. embryo, posterior to fig. 14, to show the fusion of the processes, the slight indication of the invasion of mesemchyme and the fusion of the processes with the nasal septum.

Fig. 16. Cross-section through the head of the 30 mm. embryo in the posterior region to show the ventral separation.

Fig. 17. Cross-section of the 39 mm. embryo cut slightly oblique, showing on one side the respiratory duct cut off, on the other, the connexion with the respiratory cavity.

Plate I



1



2

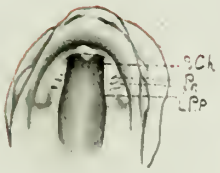

3

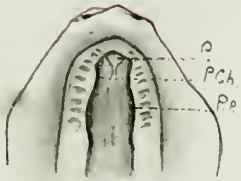

4

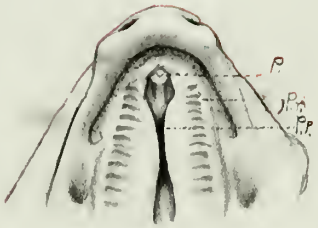

5

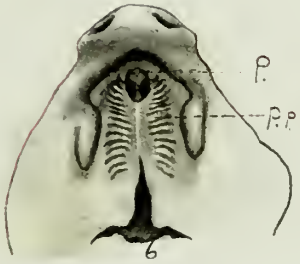

6

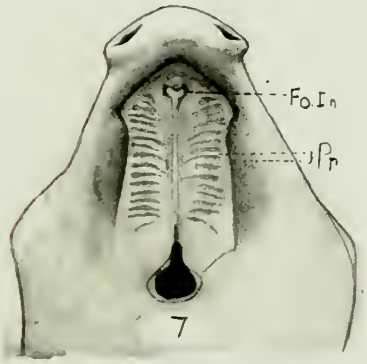

7

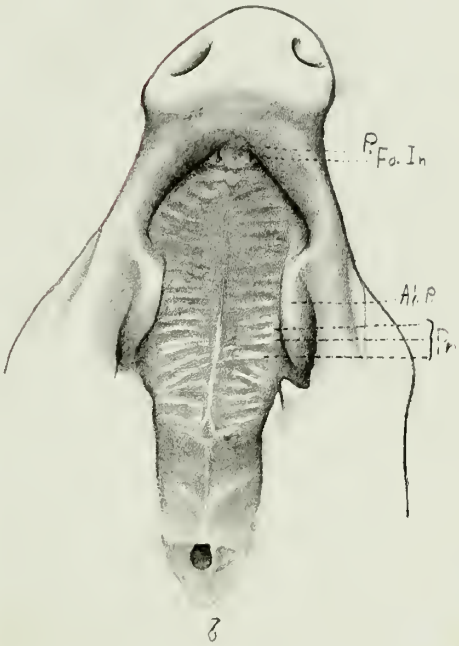

8

Plate II

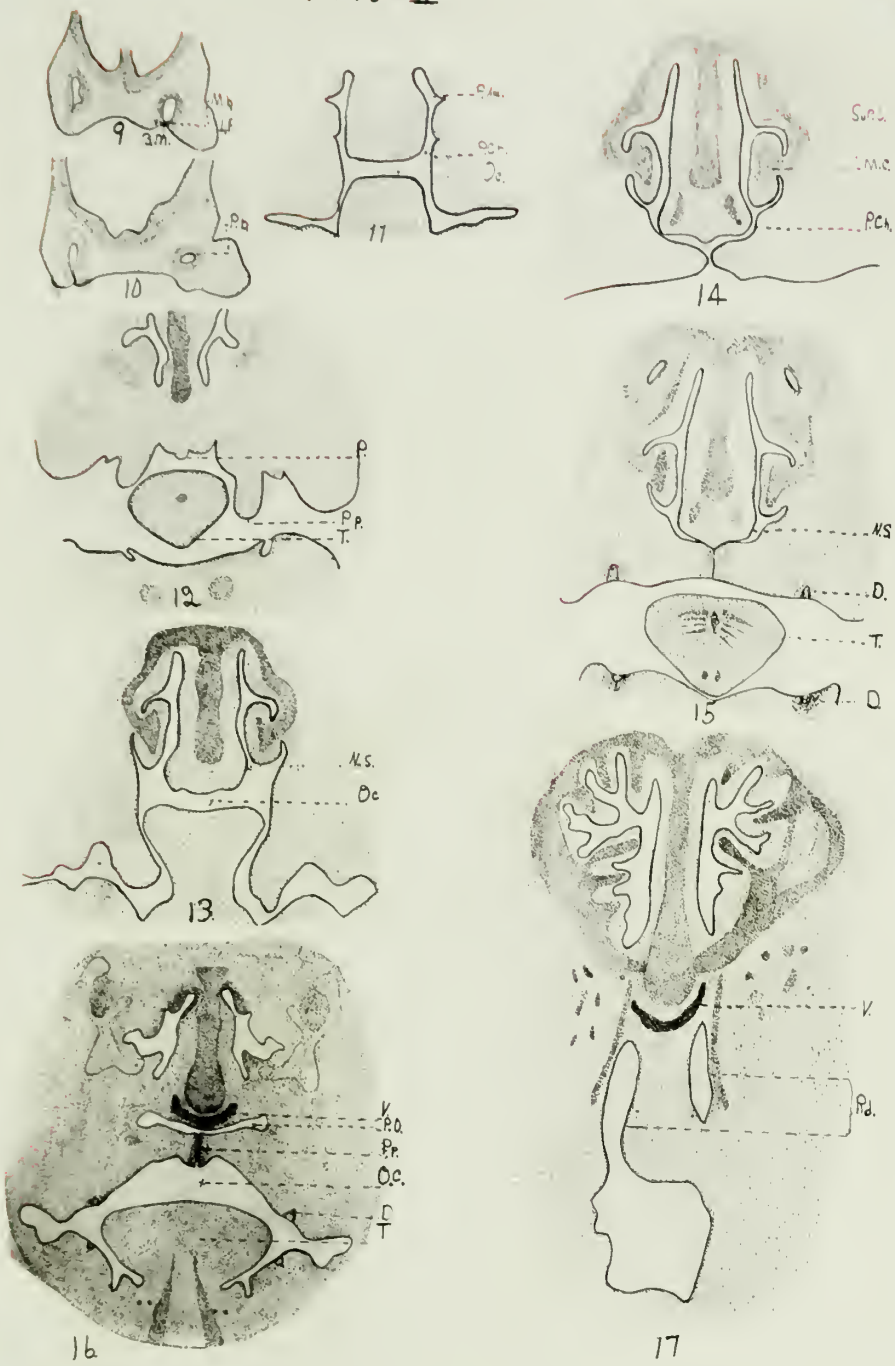

UNIVERSITY OF ILLINOIS-URBANA
3 0112 086831317